

Tromboembolismo Pulmonar com um Trombo no Coração Direito: Uma Rara Associação

Pulmonary Thromboembolism with a Thrombus in the Right Heart: An Unusual Association

Ana Antunes¹ , Rita Carvalho² , Adélia Miragaia³ 

Palavras-chave: Doenças do Coração; Embolia Pulmonar; Trombose.

Keywords: Heart Diseases; Pulmonary Embolism; Thrombosis.

A 69-year-old woman with history of high blood pressure and obesity was taken to emergency department due to asthenia, dyspnea and central cyanosis. She was conscious, but hypotensive, tachycardic, tachypneic and with increased capillary refill time. The arterial-blood gas (10 L / min) revealed metabolic acidemia, hypoxemia, hypocapnia and hyperlactacidemia and the blood test leukocytosis, neutrophilia, C-reactive protein elevation and acute renal injury. The chest X-ray showed enlargement of the right chambers and right lower lobe consolidation. Preliminary diagnosis was sepsis triggered by pneumonia with hemodynamic response to fluid therapy. However, persistent hypoxemia after 48 hours of antibiotic therapy led to pulmonary thromboembolism (PE) suspicion. Transthoracic echocardiogram revealed dilated right ventricle (RV), with septum flattening, and a large thrombus (type A) in the right atrium protruding to the RV (Figs. 1 and 2). The scintigraphy confirmed PE. The etiological study revealed left popliteal and right gemelar veins thrombosis, and heterozygosity for two polymorphisms of methyltetrahydrofolate reductase (C677T and A1298C) with hyperhomocysteinemia. She maintained anticoagulation (LMWH),² with clinical and RV function improvement and without evidence of thrombus on echocardiogram on the 10th day. However, on the 14th day, she suddenly developed dyspnea with subsequent cardiorespiratory arrest and death. ■

Declaração de Contribuição

AA, RC, AM – Conceito, colheita, análise dos dados, redação e aprovação final do artigo.

Todos os autores aprovaram a versão final a ser publicada.

¹Medicina Interna, Centro Hospitalar de Leiria, Leiria, Portugal

²Serviço de Cardiologia, Centro Hospitalar de Leiria, Leiria, Portugal

<https://doi.org/10.60591/crspmi.35>

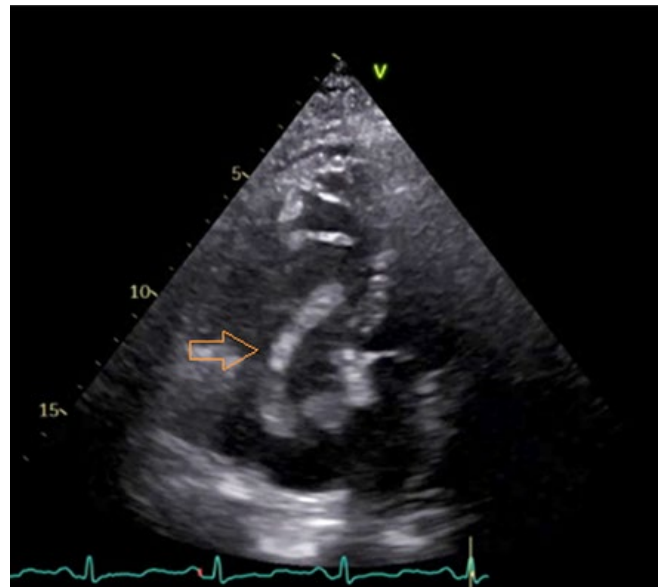


Figure 1: Transthoracic echocardiography (apical view) with a mobile thrombus in right atrium protruding to the ventricle.

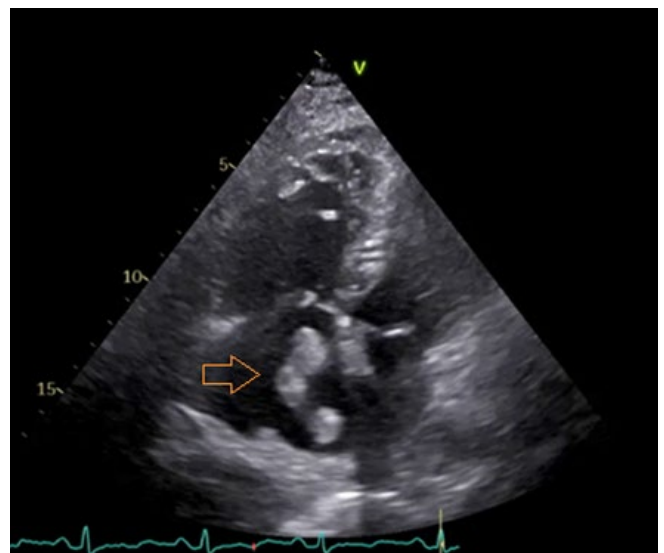


Figure 2: Transthoracic echocardiography (apical view) with a mobile thrombus in right atrium.

Contributorship Statement

AA, RC, AM - Concept, data collection, analysis, writing and final approval of the article.

All authors approved the final draft.

Responsabilidades Éticas

Conflitos de Interesse: Os autores declaram a inexistência de conflitos de interesse na realização do presente trabalho.

Fontes de Financiamento: Não existiram fontes externas de financiamento para a realização deste artigo.

Confidencialidade dos Dados: Os autores declaram ter seguido os protocolos da sua instituição acerca da publicação dos dados de doentes.

Proveniência e Revisão por Pares: Não comissionado; revisão externa por pares.

Ethical Disclosures

Conflicts of Interest: The authors have no conflicts of interest to declare.

Financing Support: This work has not received any contribution, grant or scholarship.

Confidentiality of Data: The authors declare that they have followed the protocols of their work center on the publication of data from patients.

© Autor (es) (ou seu (s) empregador (es)) e SPMI Case Reports 2023. Reutilização permitida de acordo com CC BY. Nenhuma reutilização comercial.

© Author(s) (or their employer(s)) and SPMI Case Reports 2023. Re-use permitted under CC BY. No commercial re-use.

Correspondence / Correspondência:

Ana Antunes - claudia_c.a@hotmail.com

Medicina Interna, Centro Hospitalar de Leiria, Leiria, Portugal

Rua de Santo André, 2410-197 Leiria

Recebido / Received: 2023/05/18

Aceite / Accepted: 2023/07/09

Publicado online / Published online: 2023/11/29

REFERÊNCIAS

1. Português J, Calvo L, Oliveira M, Pereira VH, Guardado J, Lourenço MR, et al. Pulmonary Embolism and Intracardiac Type A Thrombus with an Unexpected Outcome. *Case Rep Cardiol.* 2017;2017:9092576. doi: 10.1155/2017/9092576.
2. Mujer M, Saleh Y, Abro C, Kandola SK. Pulmonary embolism with right ventricular thrombus: a management dilemma. *BMJ Case Rep.* 2019;12:e229184. doi: 10.1136/bcr-2019-229184.